

# Vocal Fold Surgery in Singers

Robert W. Bastian, M.D.

Swelling of the vocal fold mucosa (wet surface layer of tissue covering the vocal fold), which interferes with vocal function, is one of the most common problems singers face. Many singers fear the swelling of laryngitis associated with upper respiratory infections, because this type of laryngitis can interfere without warning with a previously scheduled performance. However, this author has found that a more frequent source of both acute and chronic vocal fold swelling is the singer's vocal behavior.

All singers overdo it vocally at one time or another (singing or, more commonly, speaking). When this happens, fluid accumulates in the mucosa of the vocal fold. If the voice is simply rested for a few days, this kind of swelling ordinarily resolves. However, when a singer overuses or misuses his or her voice during singing or speaking on a long-term basis, chronic swellings occur as the body's protective reaction to ongoing vocal trauma. These swellings have been called by such expressions as singers' nodes, vocal nodules, vocal polyps, or polypoid nodules. When one of these entities is diagnosed, the two main treatments are voice therapy and surgery.

Voice therapy should be emphasized initially because the cause of the disorder is primarily behavioral. Thus, to facilitate resolution of the nodules, and to prevent their return or the worsening of the condition, specific items of the singer's vocal and general behavior must be changed. The elements of voice hygiene and proper voice use have been addressed by many other authors and will not be reiterated here.

When a patient in voice therapy complies for many weeks with the changes recommended, but the nodules persist *with symptoms*, surgery is the other main option to be considered. Vocal fold surgery in singers is a controversial subject. To confirm this, an informal survey of several voice teachers, laryngologists, and speech pathologists was conducted by the author. During this survey, anecdotal descriptions of both good and bad results of surgery of the vocal folds of singers were encountered. Not only did there seem to be wide variation in the surgical results that had been seen by these professionals, but their opinions about the indications for vocal fold surgery in singers differed as well. For instance, some believe that nodules can virtually always be cured with proper exercises and training of the voice, while others think that surgery is the only cure.

The author's views grow out of his experience in operating on nearly 20 singers. For these cases, comparisons have been made between preoperative and postoperative laryngeal photographs, videotapes, and videostroboscopic analyses. Furthermore, much information was gained from measurement of vocal capabilities before and after surgery, as well as from questionnaires that assessed each patient's opinion of the result of his or her surgery. Although these analyses will not be presented here in detail, they have led the author to conclude that technically proficient surgery is an effective, albeit not always indicated, option for a highly selected group of singers who have failed to be rehabilitated by medical and behavioral treatment. Because it has also become clear that deciding *when* surgery is appropriate is of major importance, elucidation of the author's indications for surgery will be emphasized in the remainder of this article.

Four case studies are presented to illustrate the basic criteria used to decide when a singer is a good candidate for surgery of the vocal folds.

## Case Report 1

A 41-year-old tenor was evaluated for severe, chronic hoarseness. He held a teaching job instructing gym classes at the high school level. His hoarseness had begun suddenly while he was yelling to be heard in the gymnasium, 8 months prior to his first examination by the author. He said that voice rest (done on his own prior to our consultation) and a change to a less vocally demanding job had not lessened his symptoms.

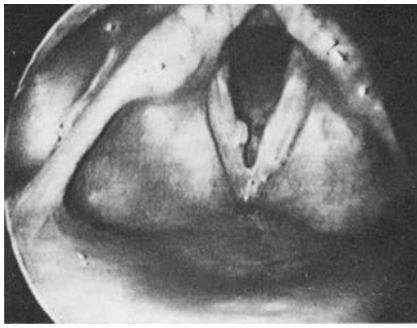
He had received 7 years of formal, classical training at the high school and college levels, but had been singing a "popular" repertoire with a "classical" technique for most of his adult life. He had been an extremely active singer at weddings, nightclubs, and so forth for many years and never had significant vocal symptoms prior to his present difficulties.

During the evaluation, his voice sounded very abnormal, with a reduced range and some intermittent diplophonia. The videostroboscopic examination showed a large traumatic polyp on the right vocal fold (Fig. 1) with a smaller contact reaction on the opposite fold. A great deal of effort seemed necessary for him to produce his voice. There was a large gap between the folds during quiet phonation, resulting in air wastage and breathiness.

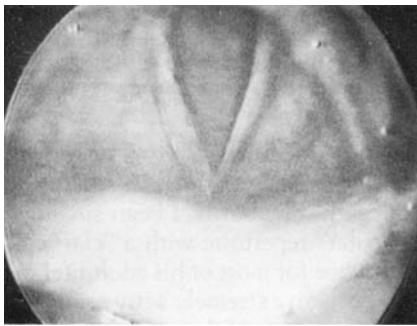
A follow-up examination a month later, after three sessions of voice therapy, revealed no change in the appearance of the polyp. He underwent surgery for removal of his vocal fold lesions. At the first postsurgical examination, 4 days later, there was already an improvement in the sound of his voice. By 2 months, his voice sounded normal and the patient felt that he had never sung better. The vocal folds appeared virtually normal with only a subtle irregularity of the right vocal fold margin (Fig. 2), and strob evaluation revealed normal mucosal oscillations. This result has remained stable for the past 2 years.

---

From the Department of Otolaryngology, The Jewish Hospital of St. Louis, Washington University School of Medicine, St. Louis, Missouri. Address correspondence to Dr. Bastian, The Jewish Hospital of St. Louis, 4910 Forest Park Boulevard, Suite 212, St. Louis, MO 63108.



**FIGURE 1.** Case 1: Traumatic polyp, right true vocal fold with contact reaction—left true vocal fold.



**FIGURE 2.** Case 1: Postoperative appearance of vocal folds.

A summary of why this man was felt to be a good surgical candidate follows:

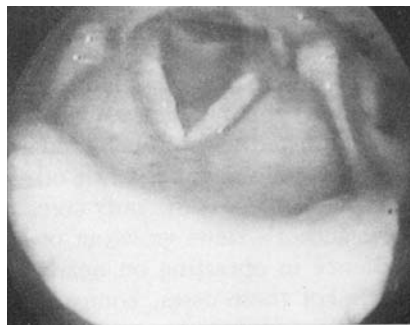
1. The lesion was large and appeared to be chronic.
2. Considerable time (9 months) had gone by from the time of onset (this included some periods of self-prescribed voice rest), and both the symptoms and the lesions causing them remained.
3. Traumatic polyps do not ordinarily resolve short of surgery when they have been present for several months.
4. The patient was very compliant with the few behavioral changes suggested in voice therapy, thereby lowering his risk of recurrence.
5. He had changed on his own to a job that was not vocally demanding.
6. He was highly motivated because he wanted to sing again.
7. Since symptoms and findings were stable and severe, he was highly accepting of the risks of surgery.

## Case Report 2

A 27-year-old operatic soprano presented with several troublesome symptoms. The worst of these were increased effortfulness of singing, loss of ability to sing softly, and vocal undependability (variability). She said that singing was too much work to be fun any more and that her voice sometimes sounded very good, but at other times it seemed slightly hoarse, with no apparent cause. In retrospect, she felt that these symptoms had been present for 2 years.

Her past history included 9 years of formal, classical training; during that time she had won several important competitions.

During the evaluation, the patient's voice sounded slightly husky but there was no gross hoarseness. Videostroboscopic analysis showed small vocal nodules (Fig. 3).



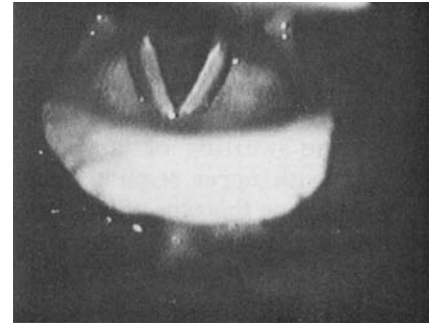
**FIGURE 3.** Case 2: Small vocal nodules.

Because this patient was still able to sing well at times, and because the laryngologist, voice teacher, and patient wanted to be sure that her nodules and/or symptoms could not be resolved without surgery, she went through changes in vocal production for speaking and singing, a change in repertoire, and even more than a month of complete silence (a measure that was her own idea). Fourteen months later, after a great deal of discussion, surgery was done to remove the nodules because she felt she could not continue her career with the limitations (see above) she continued to experience.

Within 6 weeks of surgery, the patient noted marked relief of nearly all vocal symptoms. In particular, she noted that she no longer had intermittent hoarseness and that the effort required for singing had lessened a great deal.

Furthermore, she no longer experienced the day-to-day vocal variability, which was so prominent while she had nodules.

Her examination correlated with this functional result, in that the vocal fold margins were straight and mucosal vibration was normalized (Fig. 4).



**FIGURE 4.** Case 2: Postoperative appearance.

Factors that led to the decision for surgery for this patient include the following:

1. The nodules appeared to be small and chronic.
2. Not only had symptoms been present a long time prediagnosis, but many months were allowed to pass after diagnosis, with changes in vocal behavior, and nodules persisted. This again indicated chronicity.
3. Day-to-day variability, voice fatigue, effortfulness, and inability to sing softly are all severe problems in the context of a career as a singer. In fact, prior to surgery this patient stated that she would have to give up singing if nothing further could be done.
4. The behavioral changes asked for were made consistently over a long period of time.
5. During the long period of time that passed between diagnosis and surgery, the patient gradually reached the point of full acceptance of the risks of surgery.

The two cases above illustrate successful outcomes of vocal fold surgery. The following two cases describe unsatisfactory ones. It is recognized that review of unfortunate outcomes in retrospect can be unfair; the following critiques are presented not to find fault with the surgeons involved but rather to illustrate and further define the indications for vocal fold surgery in singers.

### Case Report 3

A 24-year-old country singer with no formal voice training was examined after having had laser surgery elsewhere for vocal nodules. By her account, no changes in vocal behavior were recommended before or after this surgery, nor was any formal voice therapy suggested. In fact, a date for surgery was chosen at the time of initial diagnosis. She remembered that after surgery her voice quality was very poor for several weeks and then gradually returned to approximately its original state. At the time of examination by the author, she had the same symptoms of voice fatigue and mild intermittent hoarseness that she had noted prior to surgery. The examination revealed small vocal nodules (Fig. 5).

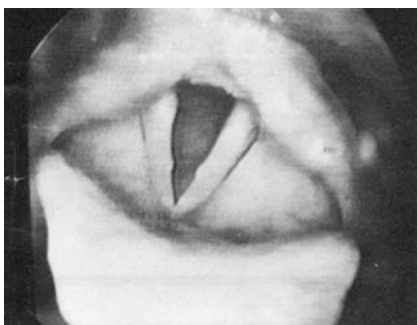


FIGURE 5. Case 3: Recurrent vocal nodules.

It could have been concluded that the surgeon had somehow failed to remove her nodules, but this did not fit with her voice having been "terrible" for three weeks postoperatively (suggesting that something was indeed done to the vocal folds). The second and more likely interpretation was that these represented *recurrent* vocal nodules. In other words, it seemed highly likely that the unchanged patterns of voice use that caused nodules in the first place had caused them to recur. This interpretation was explained to the patient, along with the rationale for asking her now to make some changes in speaking voice and other vocal behavior. Unfortunately, she declined to undergo voice therapy, saying only that she felt that the surgery had been ineffective for her problem.

What might be listed as possible errors of management in this case?

1. The cause of the swellings (inappropriate vocal and/or general behavior) was either not recognized or

not specified to the patient. Accordingly, there was no behavioral treatment.

2. There was no attempt to determine chronicity of lesions, i.e., to what degree they might have resolved without surgery. Instead, surgery was done very soon after a diagnosis was established.

3. Because the causes of the nodules were ignored by the surgeon, the problem of recurrence was not addressed.

This is the type of experience that can give this or any kind of surgery a bad reputation. The surgery here may have been done skillfully but in this patient's mind it had not.

### Case Report 4

A 46-year-old amateur, but accomplished, soprano complained of chronic hoarseness and inability to sing after a laryngeal biopsy done 7 months earlier. Although she had noted *intermittent* hoarseness for several months prior to the biopsy, she said she had not been told of any visible lesion in her larynx except "redness." Of note was the fact that she worked in a noisy food processing plant, where she had to converse over the clatter of loud machinery. Voice therapy was prescribed only *after* surgery, because she continued to have a very weak, whispery voice for several months after the procedure. Voice therapy did not seem to help her symptoms. At the time of the author's initial examination, the patient's voice was slightly breathy and lacking in projection. The videostroboscopic examination showed an area of slight concavity on the right fold margin suggestive of tissue loss (Fig. 6). Furthermore, there was no vibration of the right vocal fold mucosa, regardless of pitch or intensity.

What might have been the errors of diagnosis and treatment with this case?

1. The original, presurgical diagnosis may have been incomplete. Intermittent symptoms may suggest a functional rather than chronic voice disorder.

2. Since the nature of the problem was apparently not understood by patient or doctor, voice therapy might have been advisable before surgery.

3. Surgery may have been too vigorous or not precise enough, in that there was postoperative evidence of tissue loss and absence of mucosal vibration on one side.

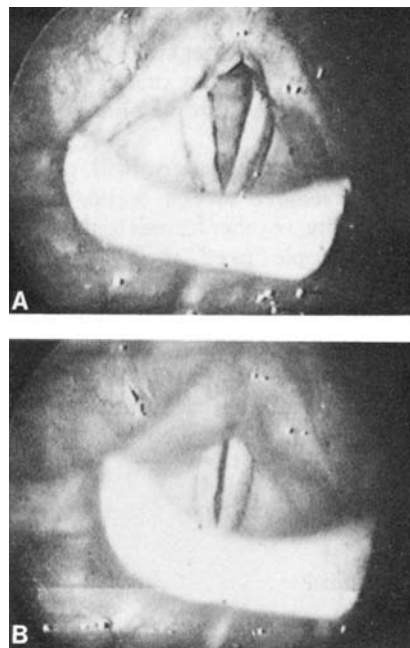


FIGURE 6. Case 4: Above, A, Concavity of right true vocal fold margin suggestive of tissue loss. Below, Gap between vocal folds during phonation.

The above cases illustrate both the good and the bad results that may be seen after vocal fold surgery. It appears to the author that determining *when* it is appropriate to operate is of primary importance, as only a small percentage of singers seen by the author ever become surgical candidates. The second major concern, when the surgical option is chosen, is that surgery be performed with extreme precision, in order to minimize the risk of bad results (scarring with resultant worsening of the voice).

The author believes that the singer must participate fully in his or her own vocal rehabilitation. To that end, the following summary of contraindications and indications for surgery is offered.

### When Laryngeal Surgery on a Singer (or Non-Singer) Should Be Deferred

1. When the chronicity of the lesion is insufficiently determined. (Will it go away with nonsurgical treatments?)

2. When there is urgency on the patient's or surgeon's part. Typically, the full nature and optimal handling of any individual case becomes clearer in the context of serial (at least two) examinations, preferably at least 6 weeks apart.

3. When the patient does not accept the role his or her behavior played in causing the lesion or is noncompliant with behavioral changes requested.

4. When the patient will not or cannot remove several occupational, personality, or other hazards to the voice (some people "need" their nodules).

5. When the patient is not sufficiently accepting of risks; i.e., the voice could be worse after surgery than before.

6. When visible lesions are present but symptoms are gone after behavioral and/or medical treatments.

### When Surgery May Be Appropriately Considered for a Singer (or Non-Singer)

1. When there is a persistent vocal fold lesion *with symptoms* after

- the patient has been educated about the voice in general and his own problem in particular;
- appropriate vocal and general behavioral modification has occurred and is consistent;
- significant time has passed, allowing at least two examinations;
- the patient has made a strong personal decision to have surgery; and
- the risks of surgery are fully accepted.

### References

1. Bastian RW: Laryngeal image biofeedback for voice modification. Presented at the Fourteenth Annual Symposium for the Care of the Professional Voice, June 1985, Denver, CO. Transcripts in preparation.
2. Bouchayer M: Microsurgery for benign lesions of the vocal folds. ENT Journal (in publication).
3. Brodnitz FS: Results and limitations of vocal rehabilitation. Arch Otol 77:148, 1968.
4. Gould WJ, Lawrence VL: Surgical Care of Voice Disorders. New York, Springer-Verlag, 1984.
5. Kambic V, et al.: Vocal cord polyps: incidence, histology and pathogenesis. J Laryngol Otol 95:609, 1981.
6. Kleinsasser O: Microlaryngoscopy and Endolaryngeal Microsurgery: Technique and Typical Findings, 2nd ed. Baltimore, University Park Press, 1979.
7. Kleinsasser O: Pathogenesis of vocal cord polyps. Ann Otol Rhinol Laryngol 91:378, 1982.
8. Strong MS, Vaughn CW: Vocal cord nodules and polyps—the role of surgical treatment. Laryngoscope 81:911, 1971.
9. Tucker HM: Monographs in Clinical Otolaryngology—Surgery for Phonatory Disorders. New York, Churchill Livingstone, 1981.